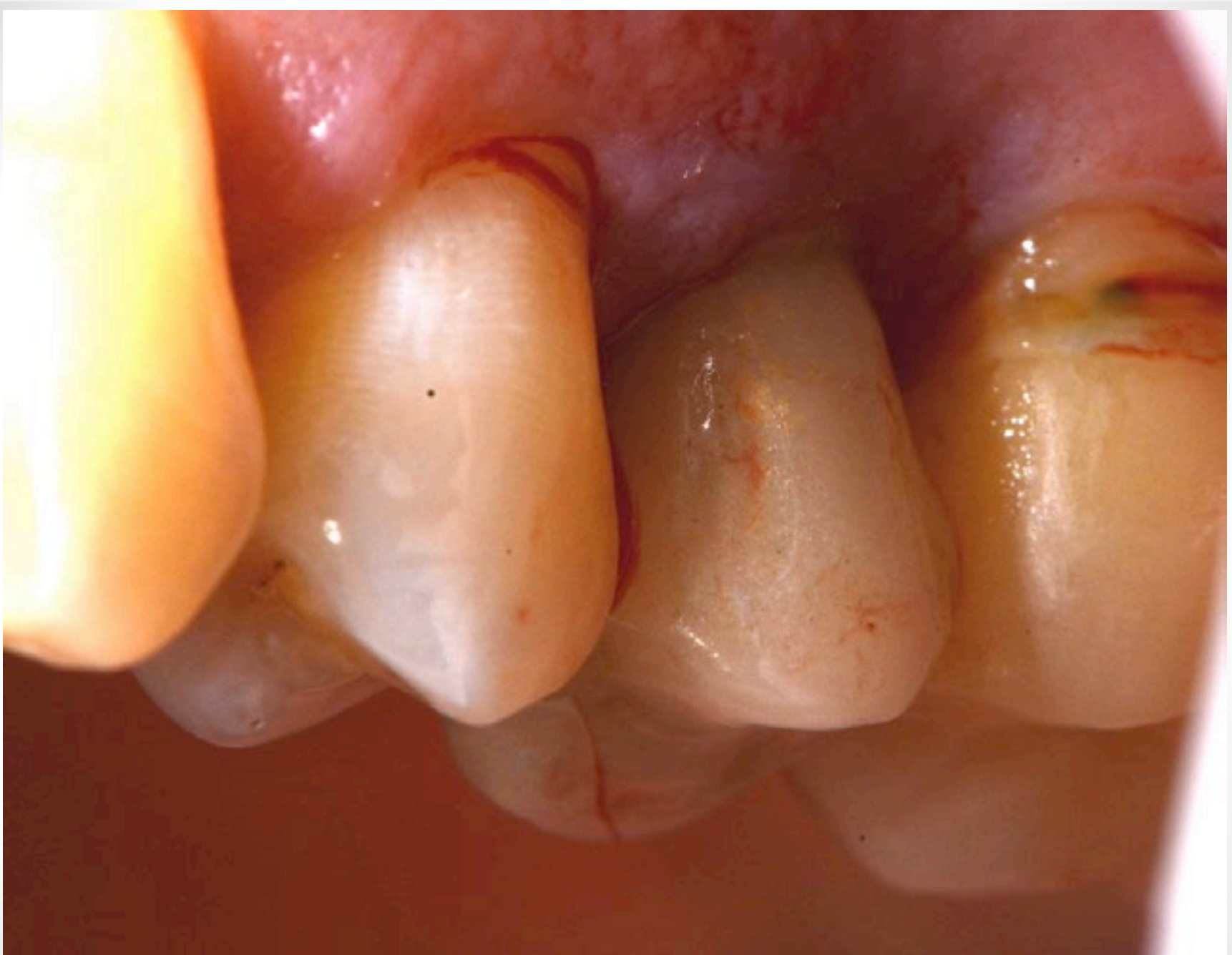

# Benex Case Study

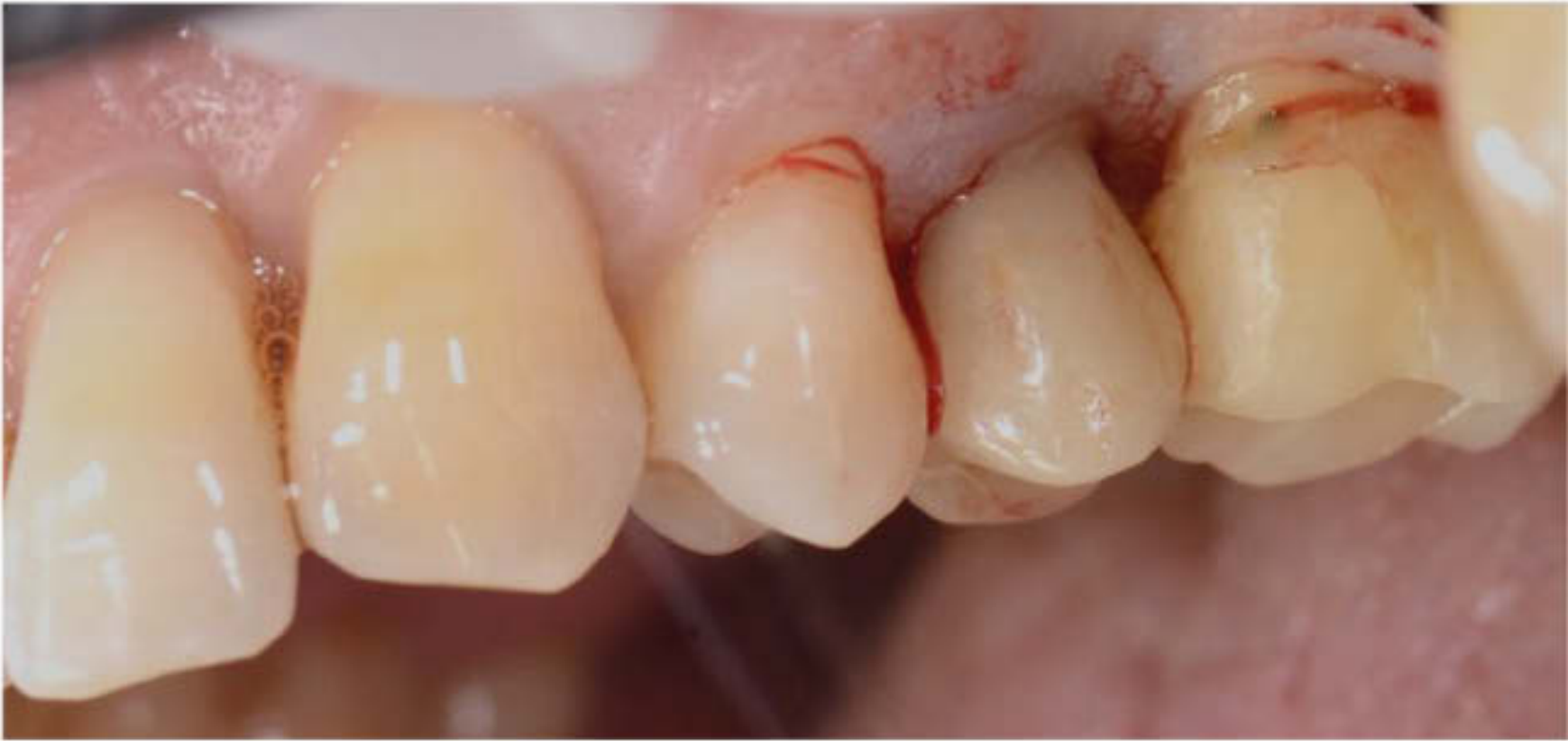Dr. Dean Licenblat

Director Sydney Dental Aesthetics & Implants

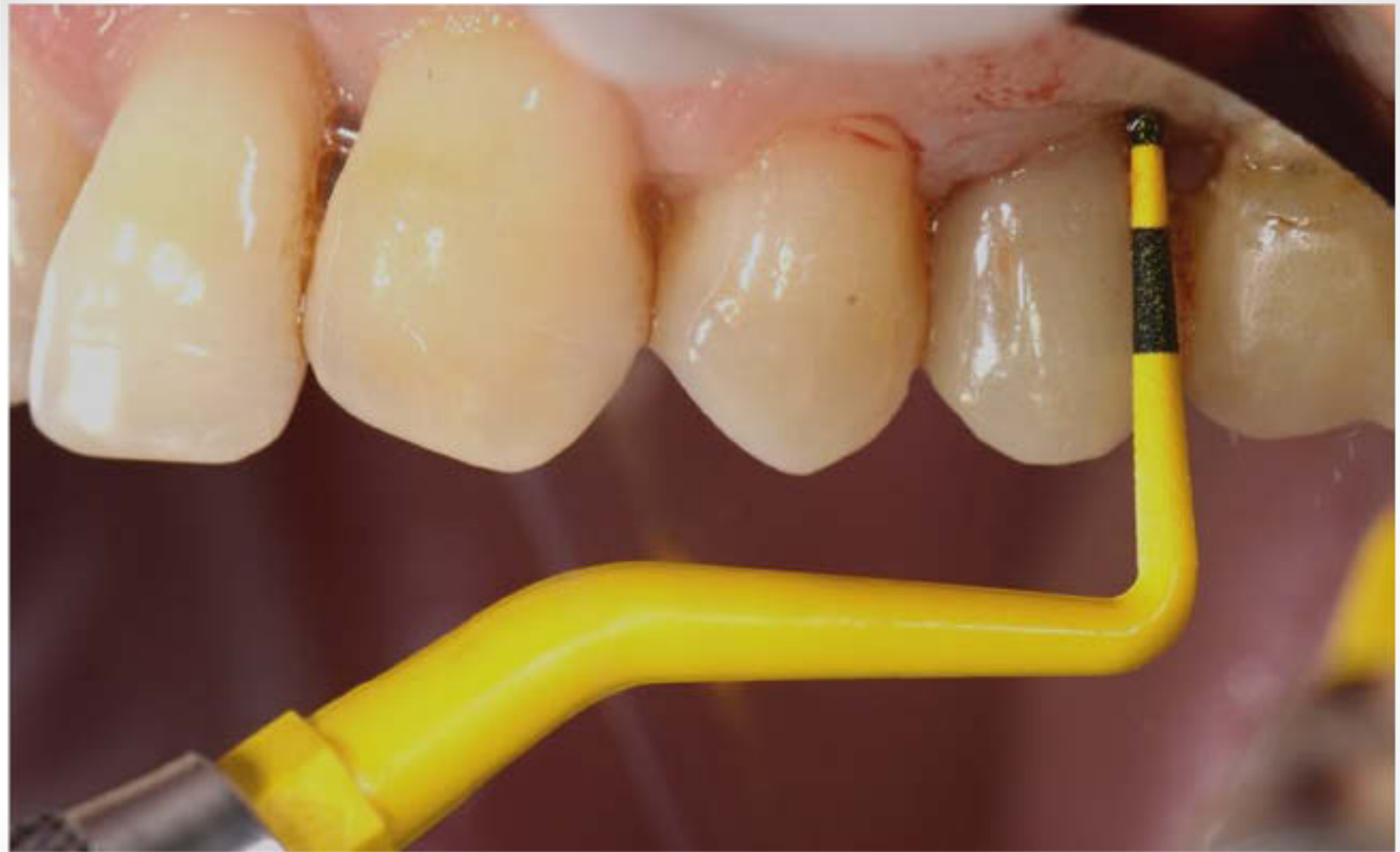Bdent (USyd), MSc (Oral Implantology) Goethe, DICOI



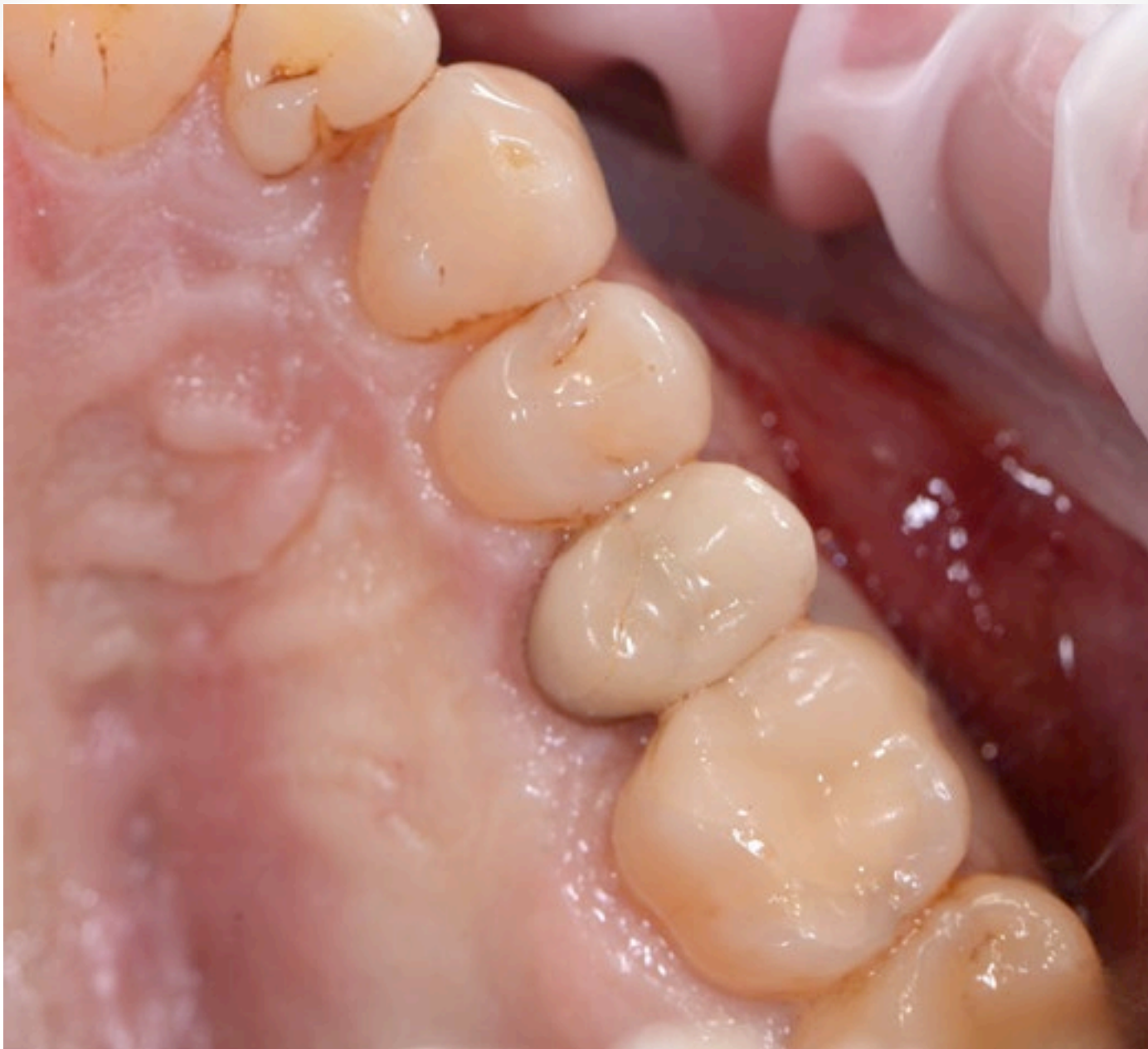**Cracked Root & Failed RCT**



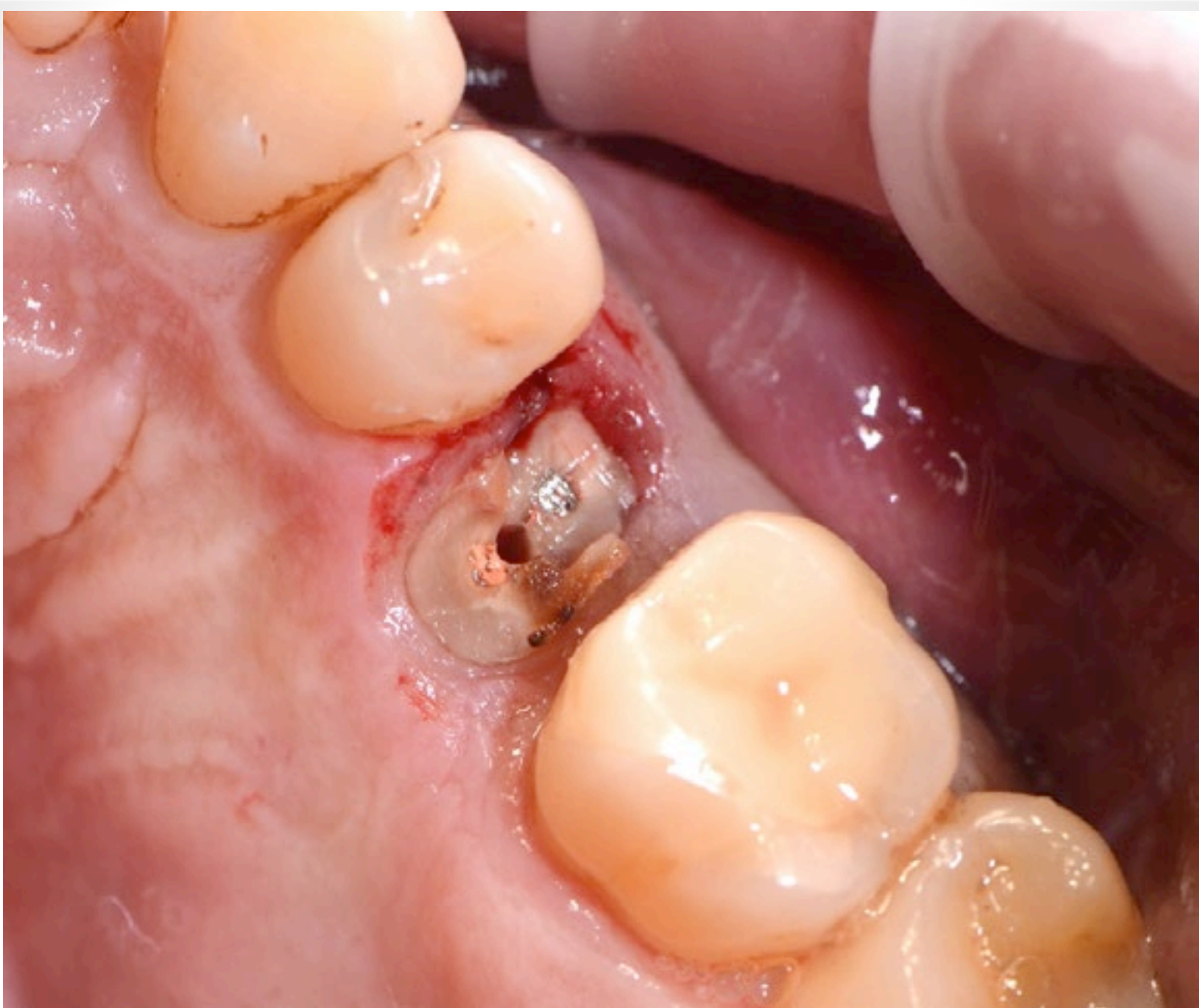**Pre-Op**



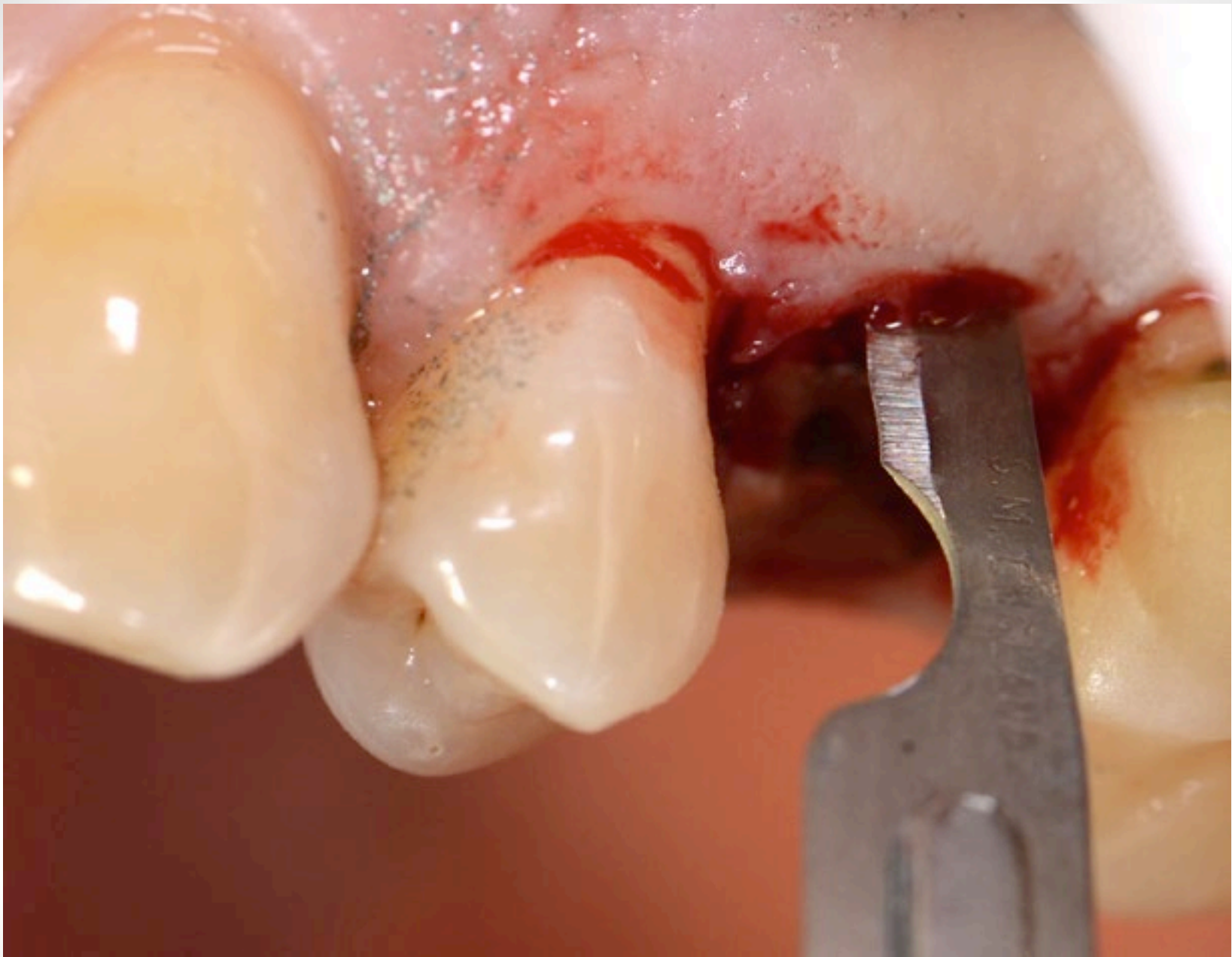**5mm probing depth at crack site**



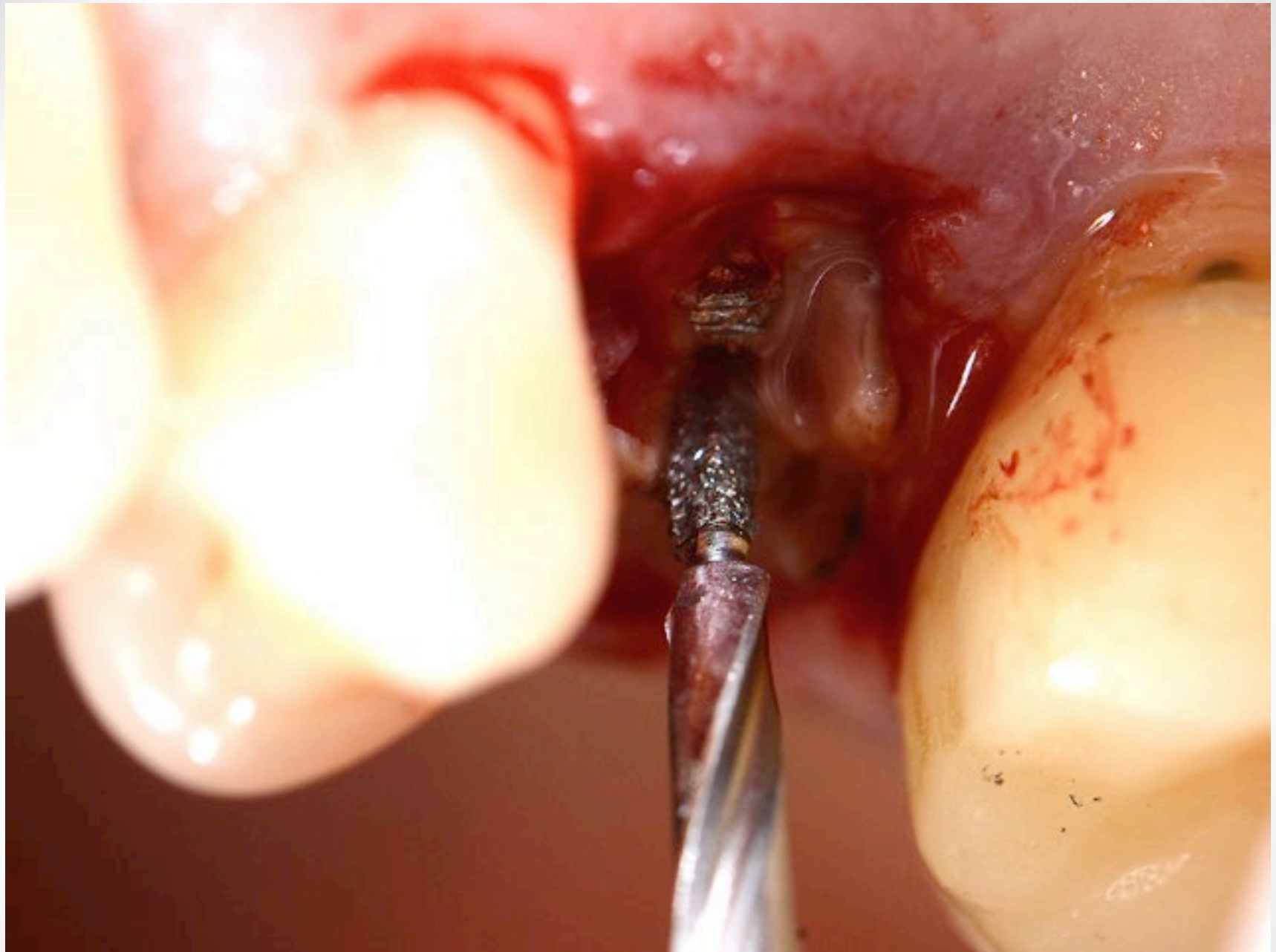
**Occlusal Pre-Op**



**Decoronation**

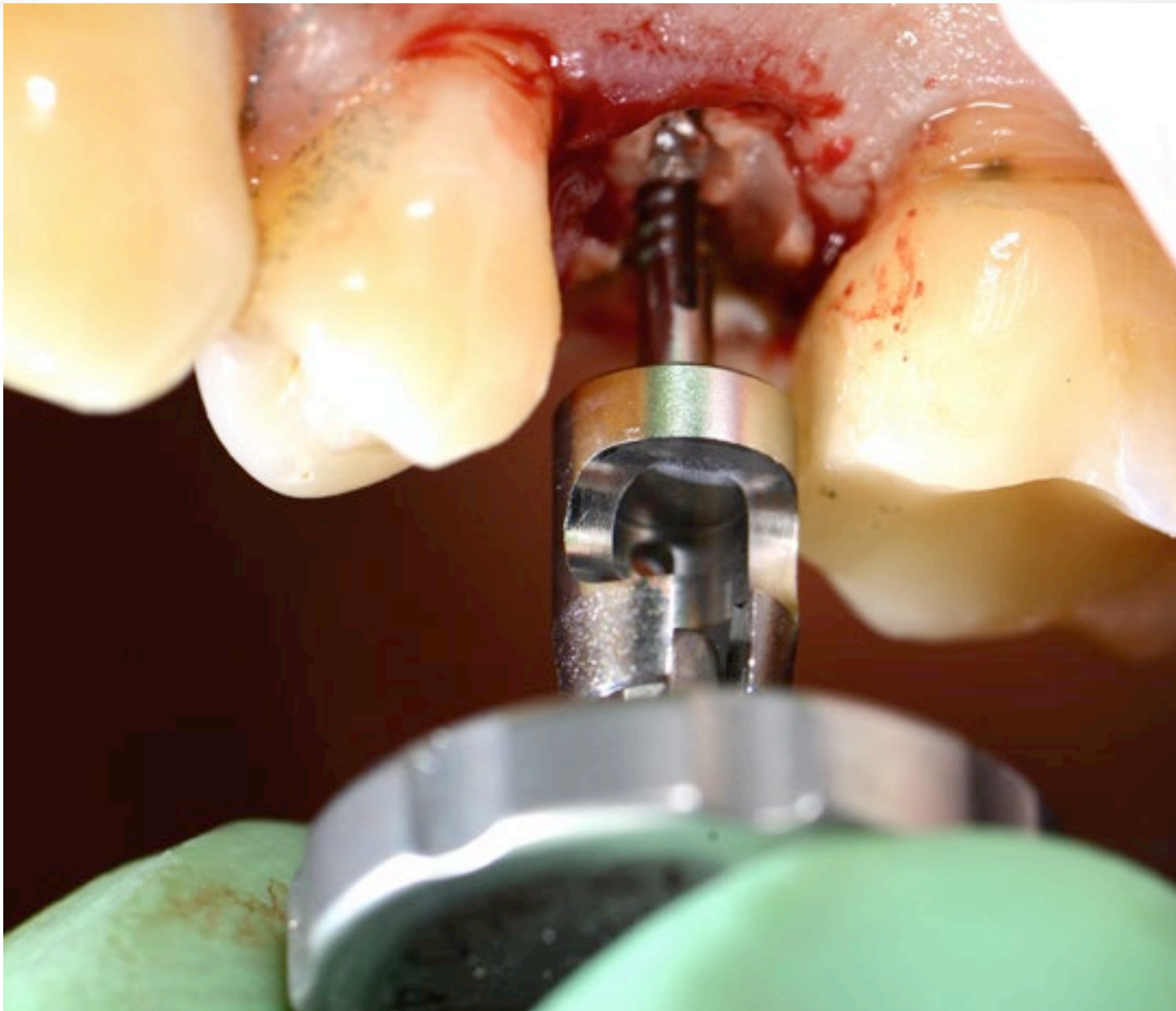

**Sulcular Incision**

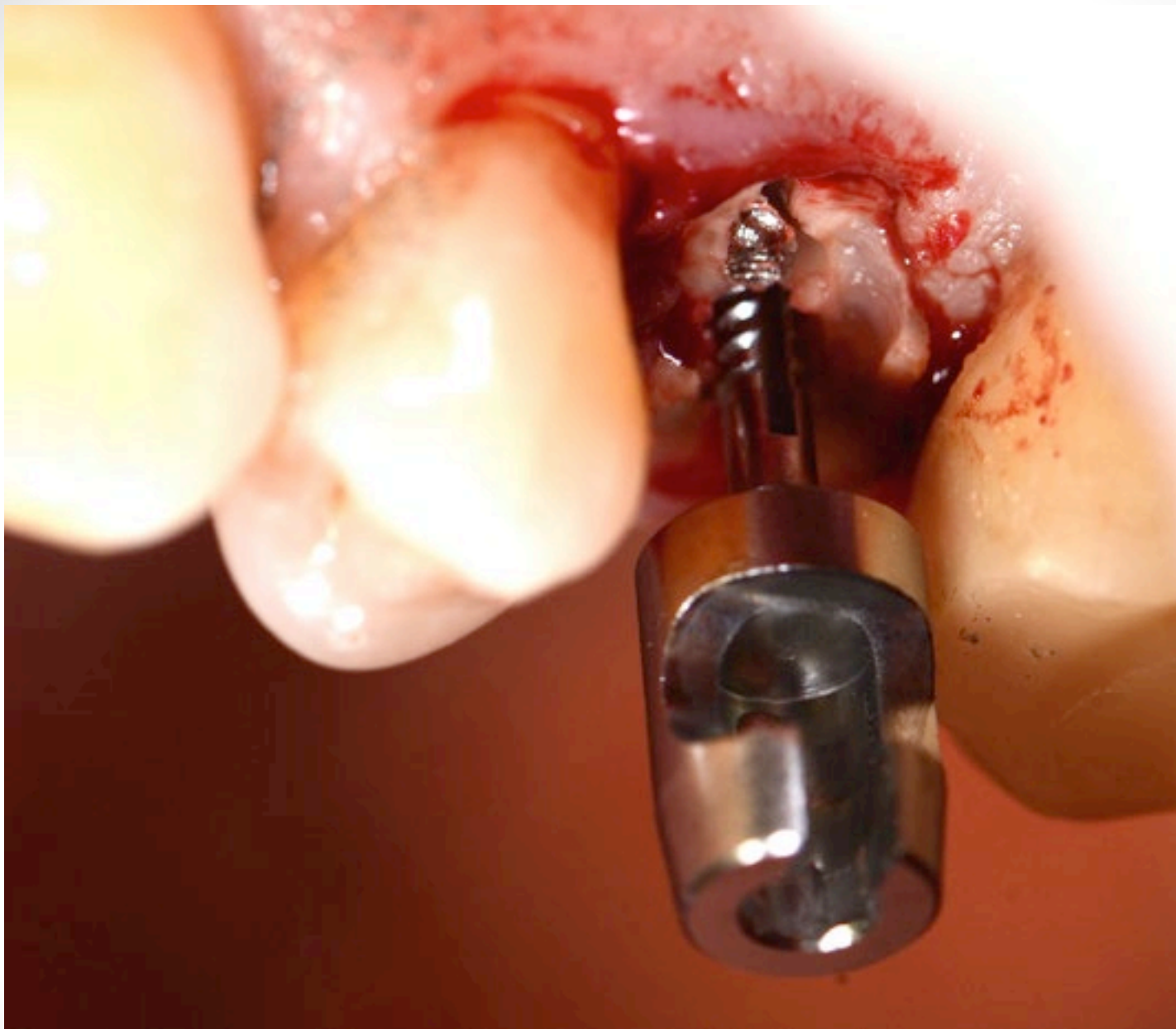

**Benex Drill**

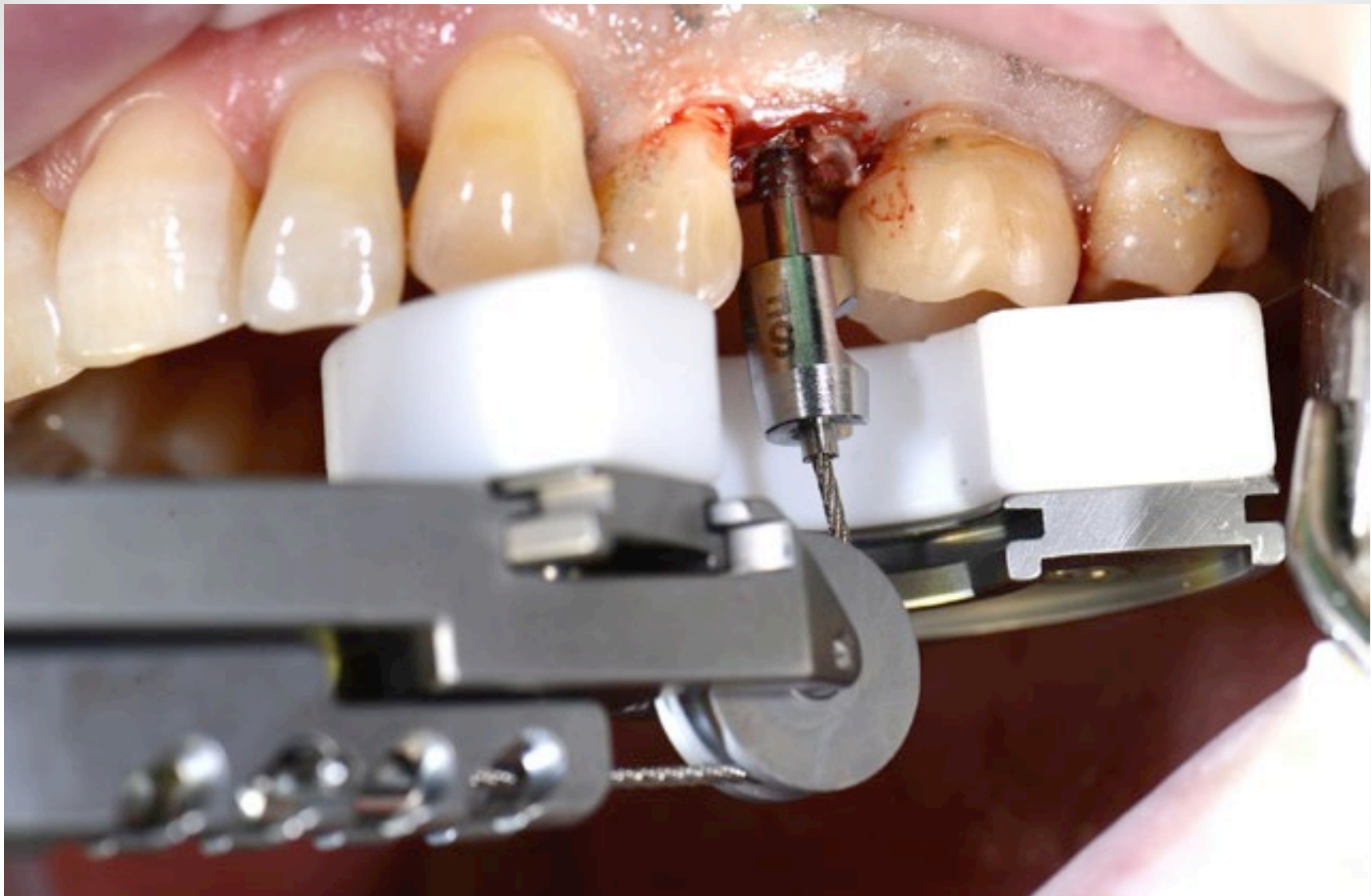




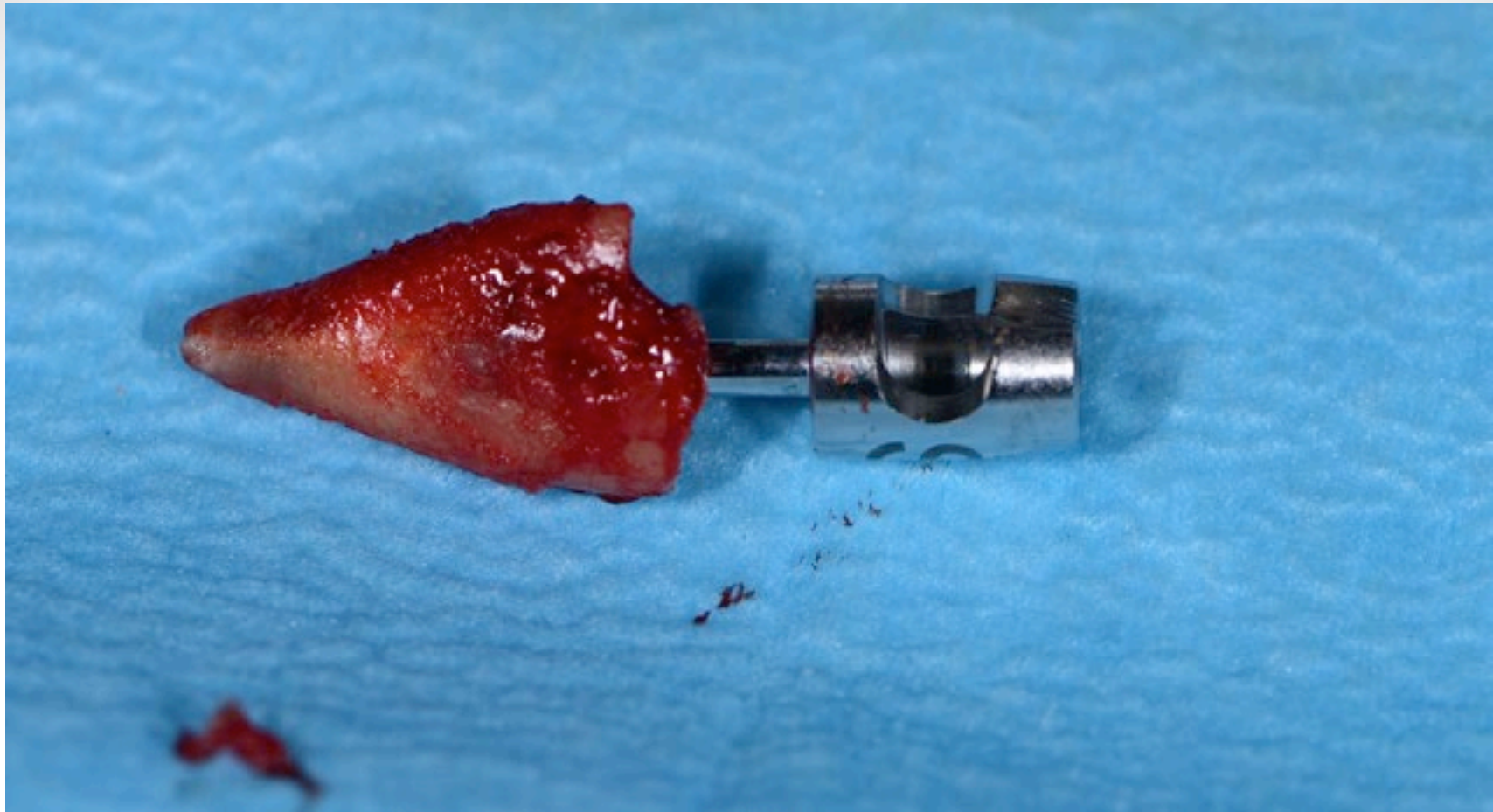
**Fixation of Benex Removal Post**



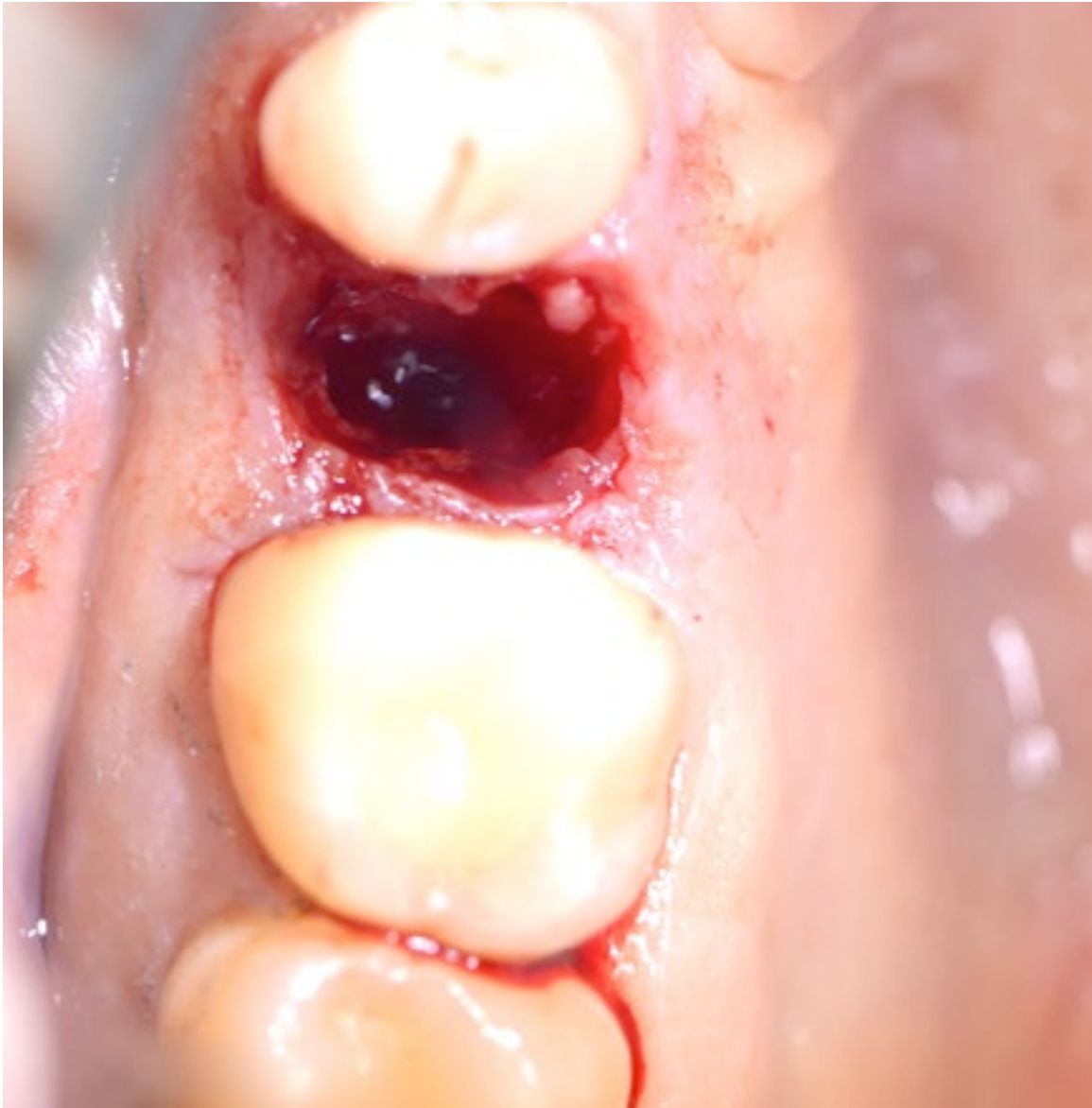**Benex Removal Post in situ**



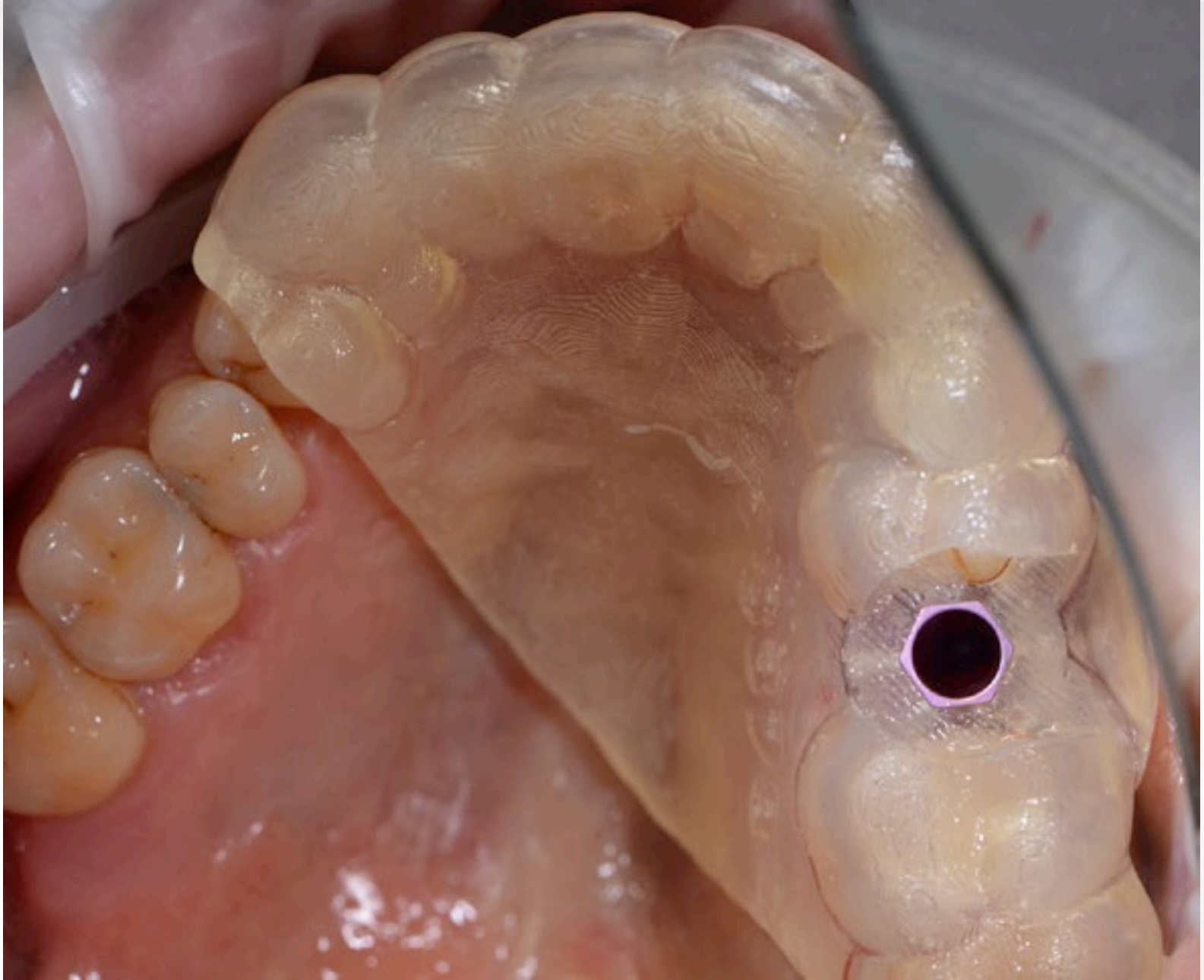
**Benex Extraction in Progress!**



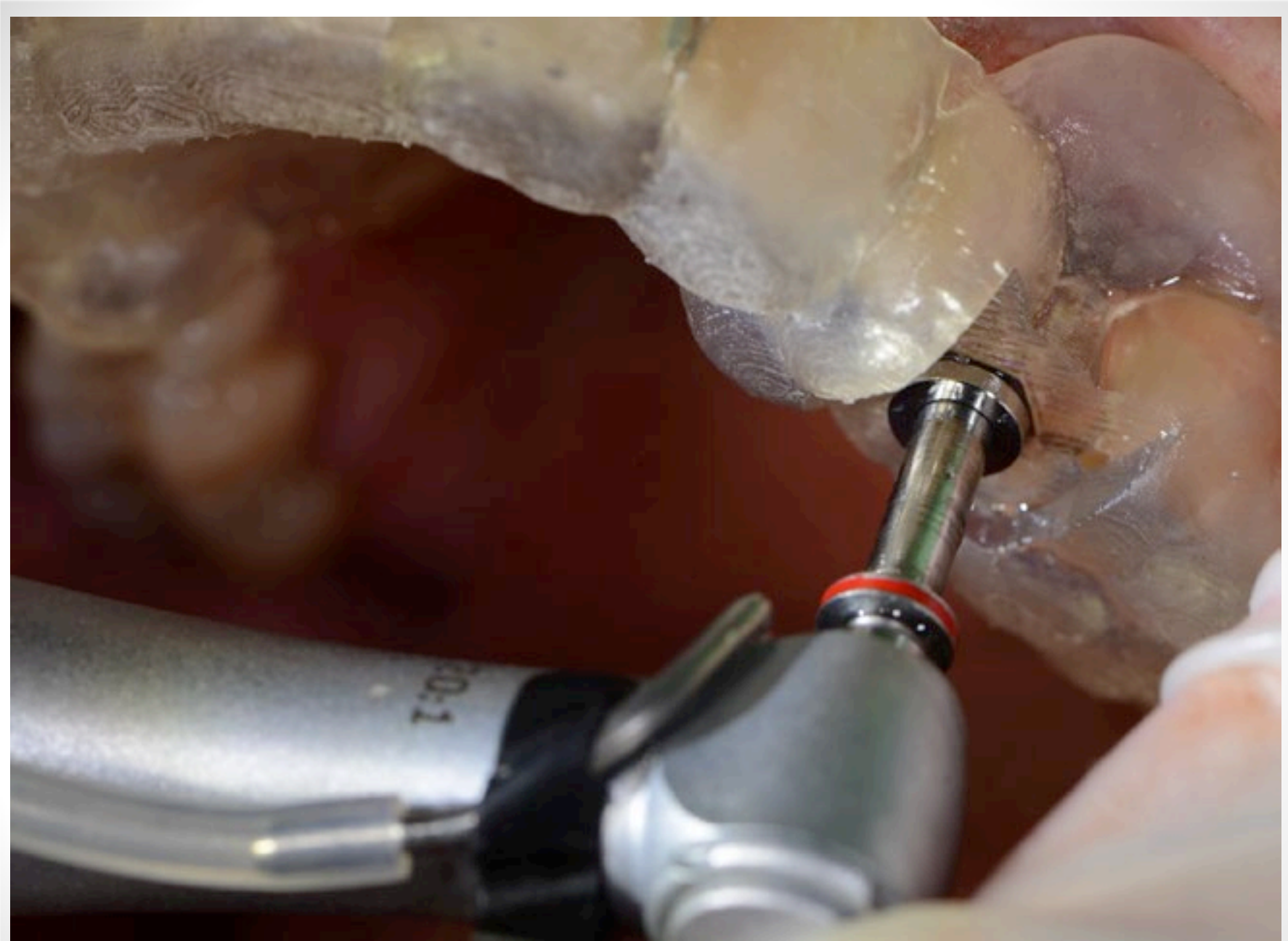**Removed Root (Total Extraction time 2 mins 40 sec)**



**Perfectly preserved socket architecture with minimal to no Bone damage or Soft Tissue mutilation**



**Simplant Surgical Guide**

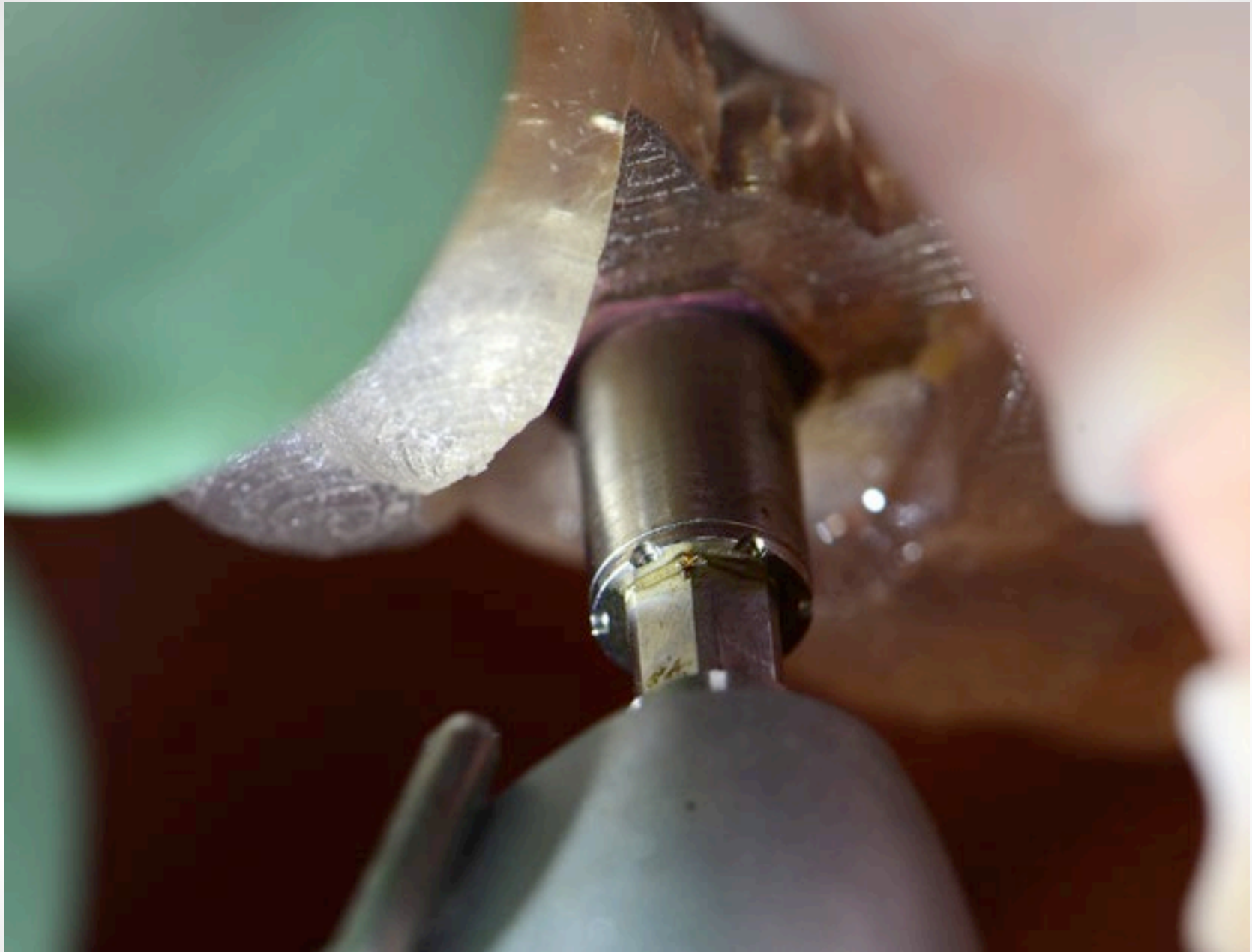


**Fully Guided Osteotomy Preparation**

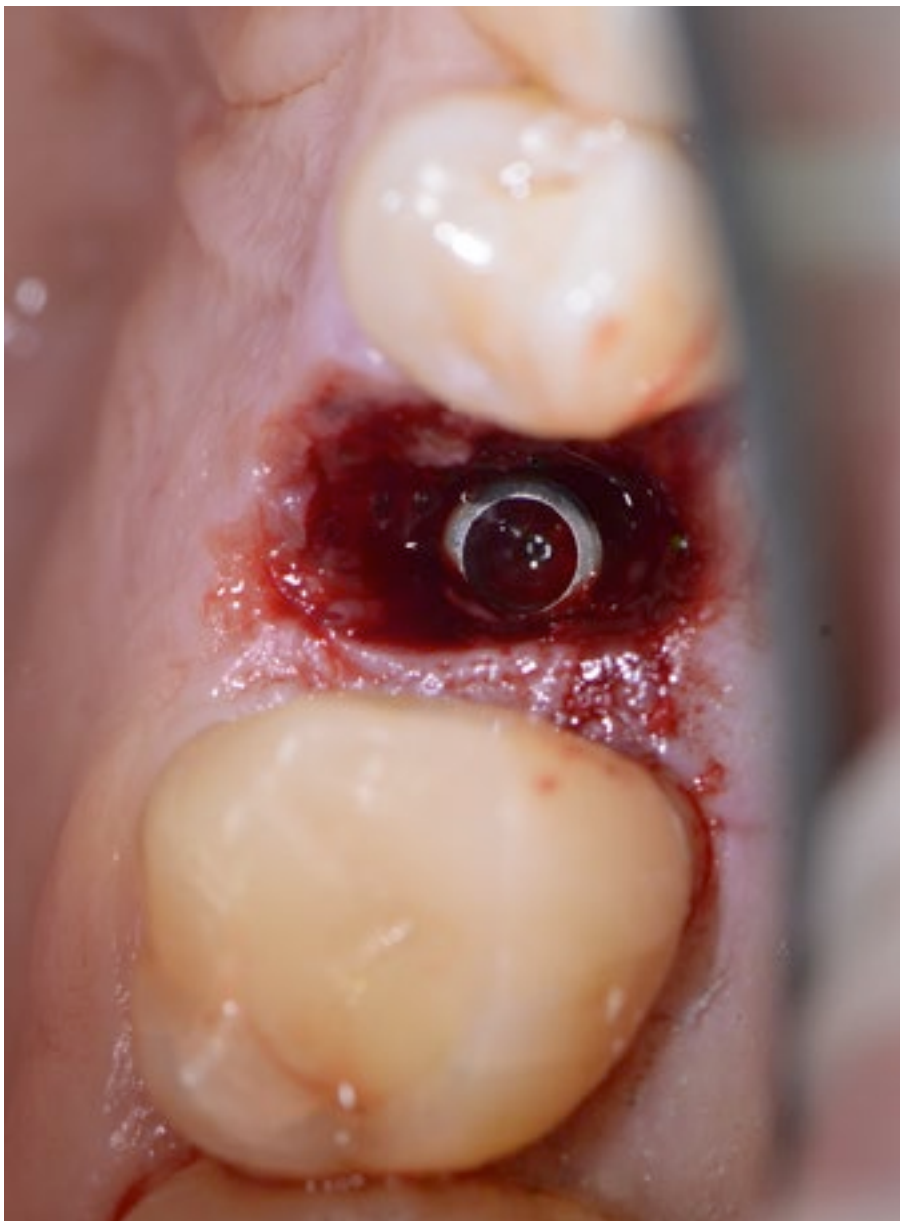

**Fully Guided Ankylos C/X Implant A3.5 x 14mm**

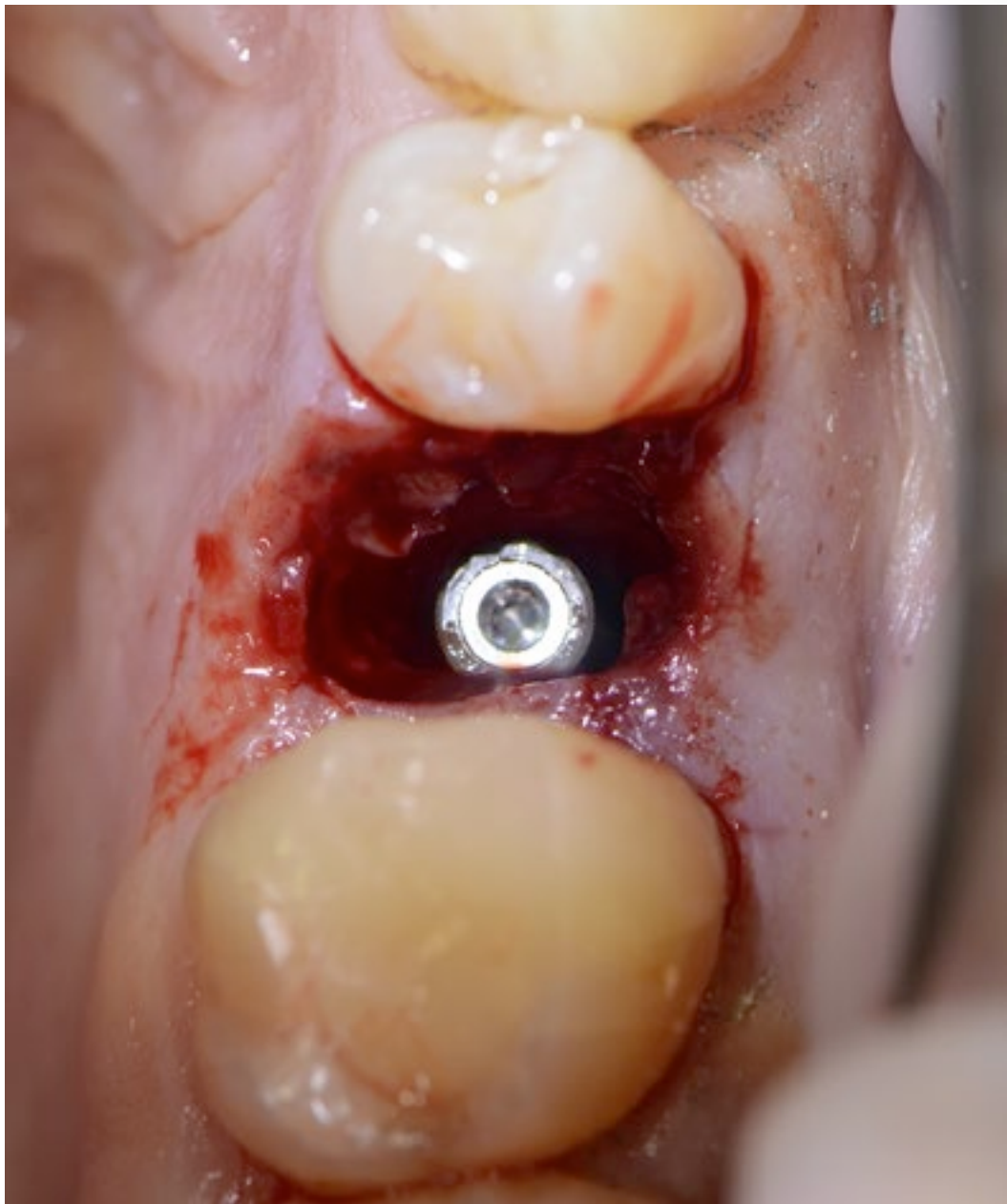




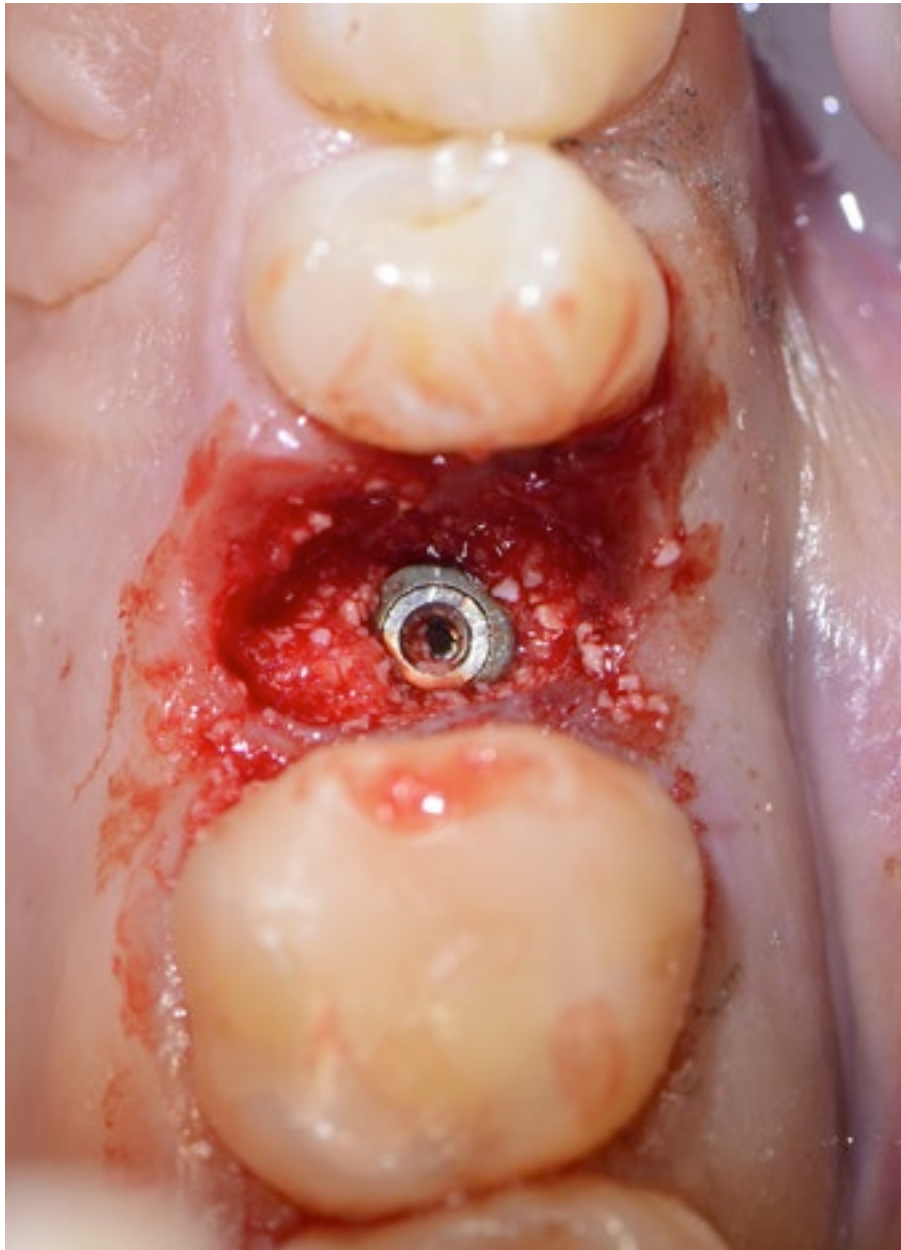
**Fully Guided Ankylos C/X Implant A3.5 x 14mm**



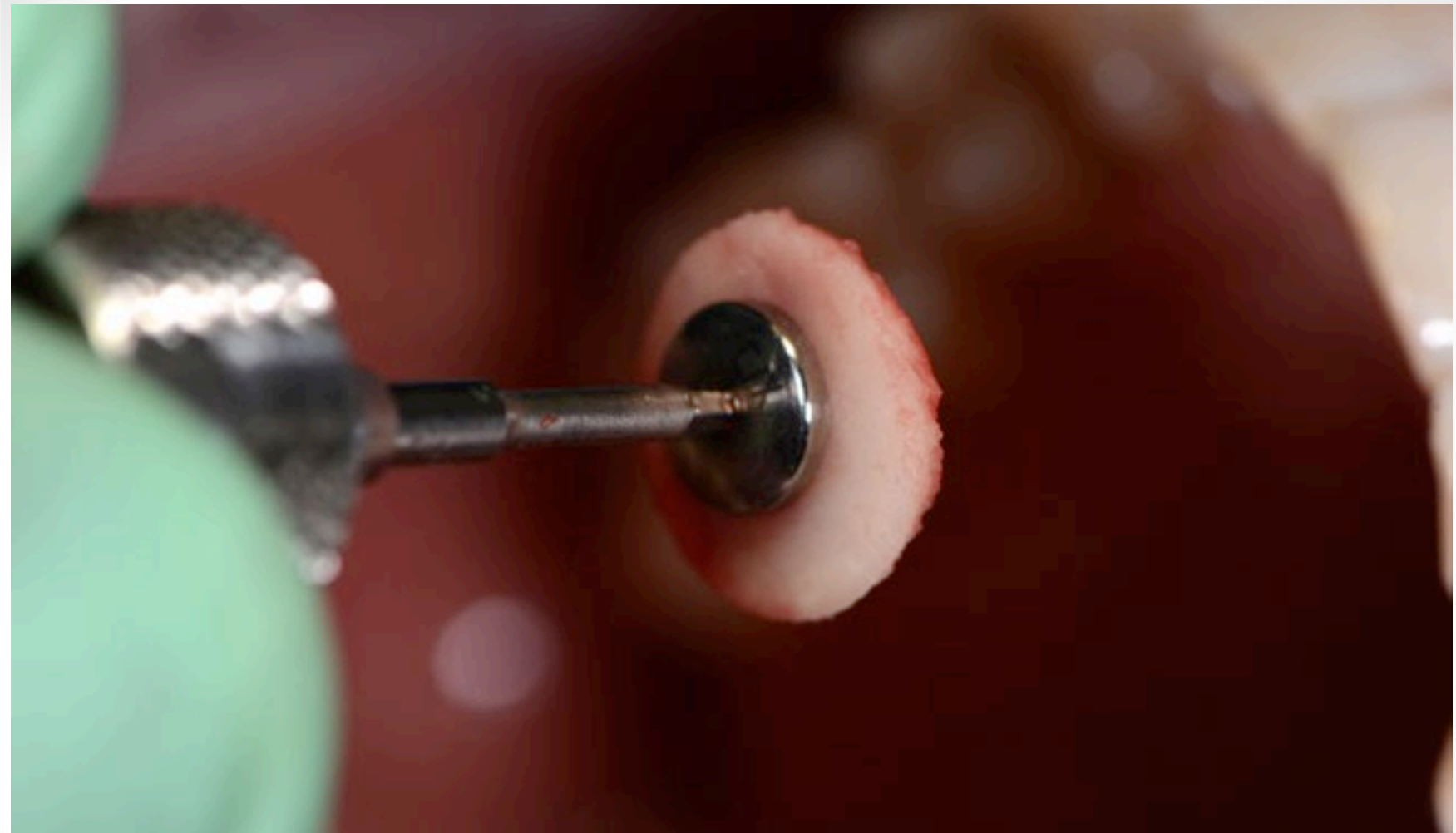
**Implant Placed – No Buccal bone lost during extraction so no need for full flap & GBR greater predictability for success**



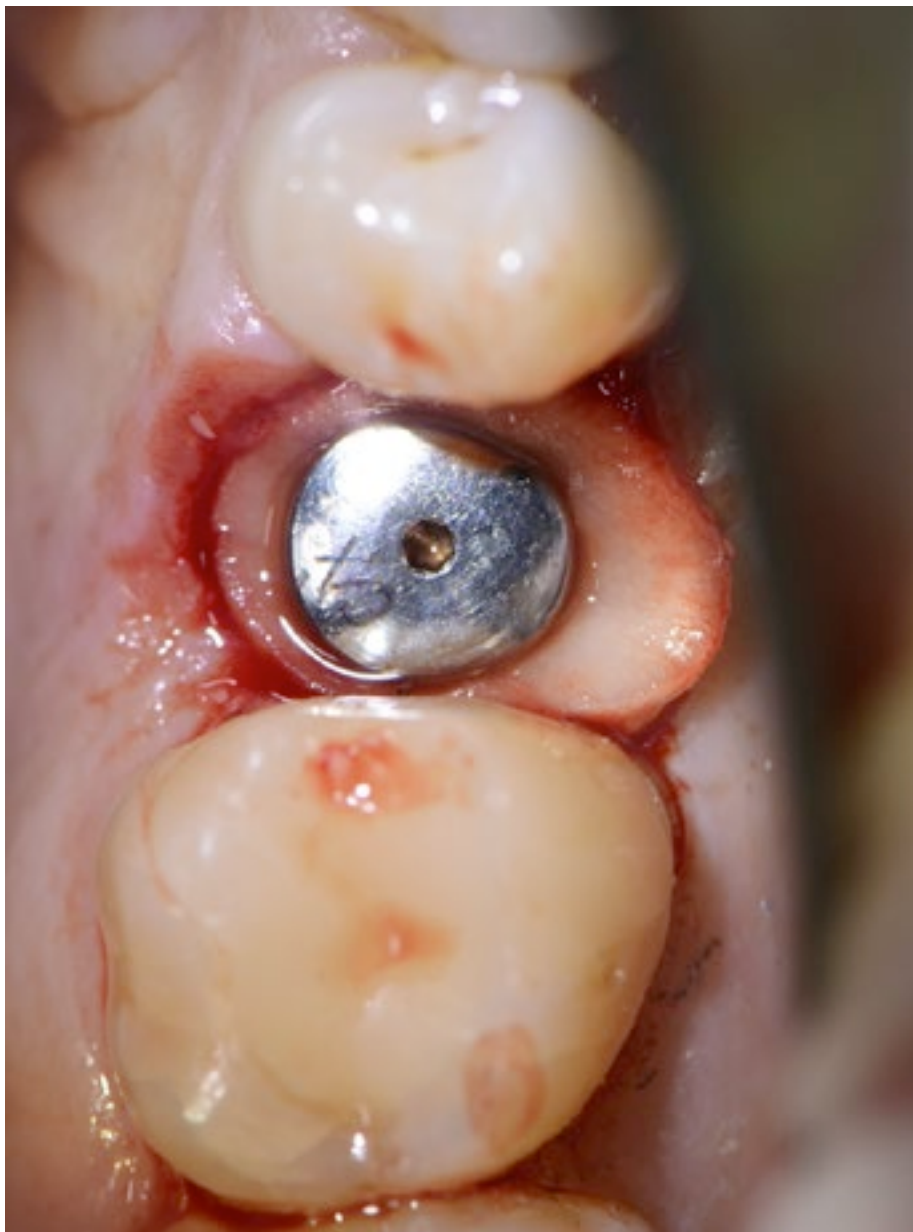
**Cover Screw Placed**



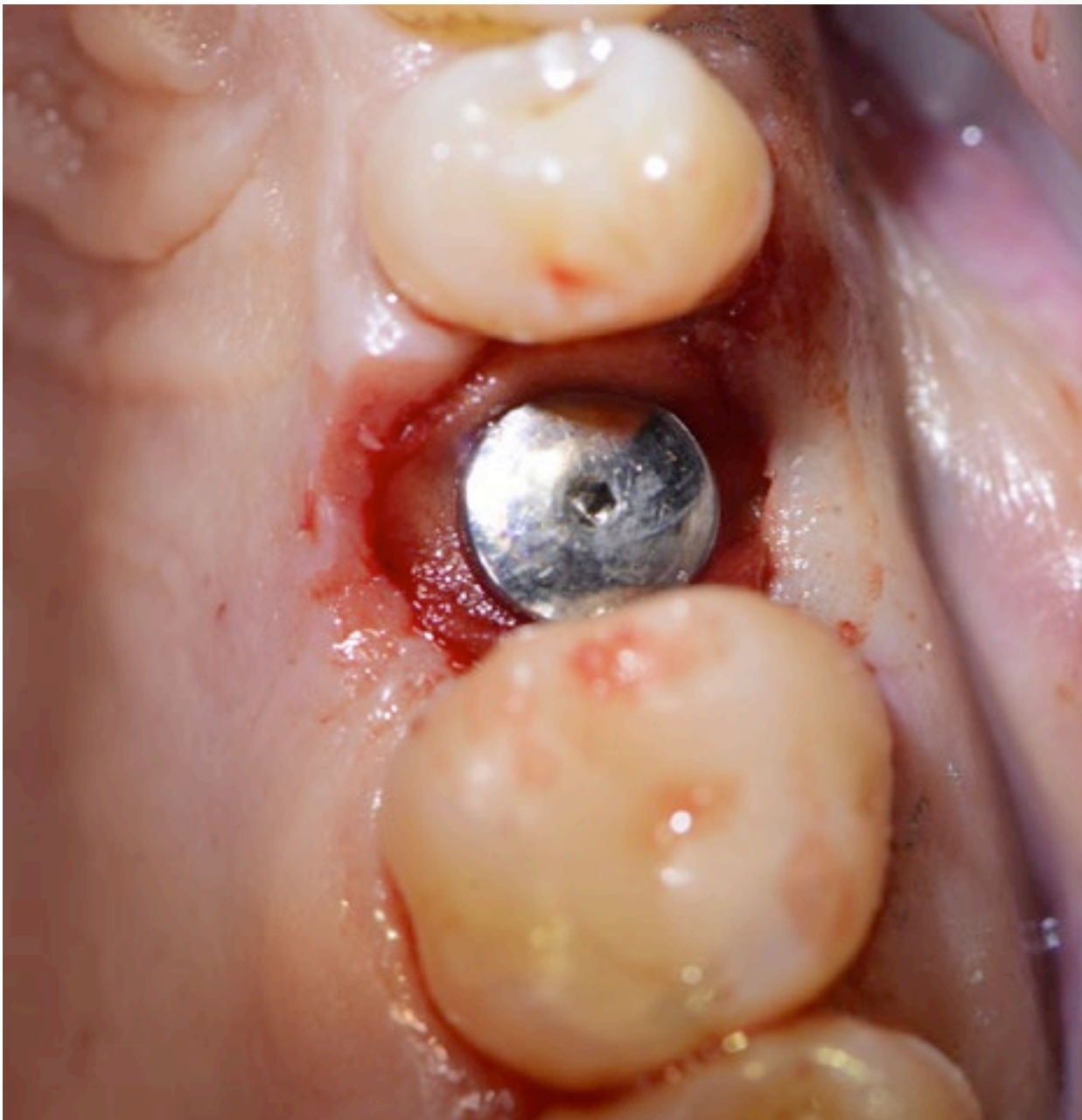**Xenograft & Collagen GBR**



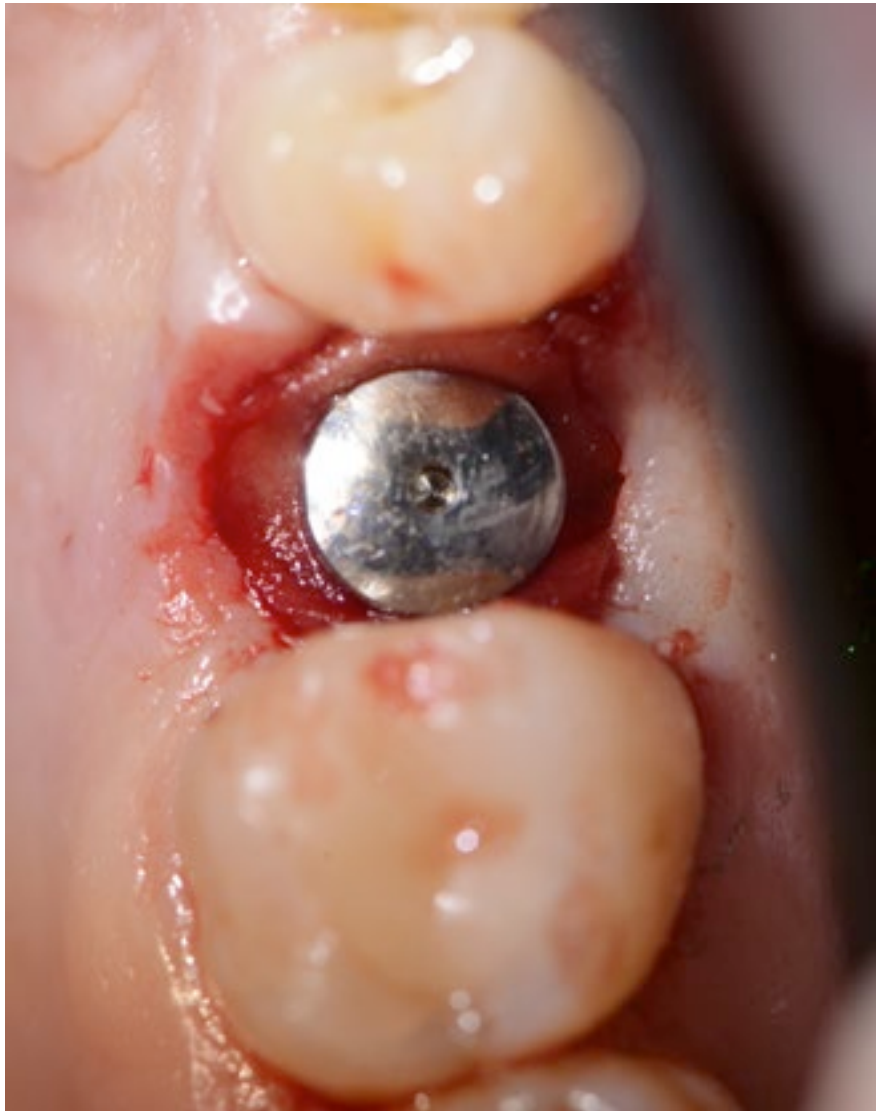**Dense Collagen Plug attached to Membrane Screw to act as Socket  
& GBR protection**



**Membrane screw fixates to thread within the Cover Screw -  
unique to Ankylos system. This firmly holds the collagen in place**



**Collagen tucked into socket margins – no need for sutures!**



**Case Complete – Everything as predicted as Benex allowed preservation of site.**